

Evaluating the Preclinical Efficacy of Photobiomodulation in Alleviating Neuropathic Corneal Pain: A Behavioral Study

Mohd. Afzal Khan, BSc, BDS,¹ Gehan Fatima, BDS, PhD,¹ Akm Ashiquzzaman, MS,¹ Sang Seong Kim, PhD,¹ Hyuksang Kwon, PhD,¹ Young Ro Kim, PhD,² Euiheon Chung, PhD^{1,3}

Purpose: Neuropathic corneal pain (NCP) is a debilitating condition characterized by persistent pain due to corneal nerve damage or dysfunction. Millions of individuals and their families endure the significant impact of chronic pain. Effective management strategies are crucial yet limited, prompting the exploration of innovative treatments such as photobiomodulation (PBM).

Design: In vivo preclinical therapeutics investigation in mice.

Subjects: Thy1-YFP mice.

Methods: This study evaluates the efficacy of PBM in treating NCP across 4 animal models: normal control, sham control, pulled nerve, and full transection (FT). Behavioral assessments, including the von Frey test (VFT) for mechanical sensitivity and the eye-wiping test (EWT) for chemical sensitivity, were employed to evaluate the therapeutic impact of PBM till day 56 (D-1, D1, D3, D5, D7, D14, D28, D42, and D56).

Main Outcome Measures: Advances in therapeutic approach for NCP through the potential of PBM.

Results: Photobiomodulation significantly reduced behavioral manifestations of pain in the pulled nerve model (VFT: no PBM [D1 = 0.043 ± 0.044 , D56 = 0.05 ± 0.014] and PBM [D1 = 0.050 ± 0.008 { P value = 0.18}, D56 = 0.09 ± 0.014 { P value = 0.02}], EWT: no PBM [D1 = 11.96 ± 0.47 , D56 = 12.11 ± 0.15] and PBM [D1 = 11.73 ± 0.18 { P value = 0.2}, D56 = 11.22 ± 0.31] [P value = 0.01]) and FT model (VFT: no PBM [D1 = 0.022 ± 0.0028 , D56 = 0.023 ± 0.0047] and PBM [D1 = 0.024 ± 0.0028 { P value = 0.2}, D56 = 0.073 ± 0.0094] [P value = 0.02]), EWT: no PBM [D1 = 13.1 ± 0.14 , D56 = 13.36 ± 0.30] and PBM [D1 = 12.86 ± 0.41 , { P value = 0.2}, D56 = 12.53 ± 0.41] [P value = 0.04]), suggesting an effective reduction of pain sensitivity and an increase in corneal nerve function. The temporal patterns also suggest that early intervention with PBM, initiated shortly after nerve injury, may be crucial for preventing the chronic progression of NCP.

Conclusions: These outcomes support PBM as a promising nonpharmacologic intervention for NCP; this not only reinforces the potential of PBM in NCP treatment but also provides a foundation for future clinical applications in managing corneal neuropathy.

Financial Disclosure(s): The author(s) have no proprietary or commercial interest in any materials discussed in this article. *Ophthalmology Science* 2025;5:100680 © 2024 by the American Academy of Ophthalmology. This is an open access article under the CC BY-NC-ND license (<http://creativecommons.org/licenses/by-nc-nd/4.0/>).



Supplemental material available at www.ophtalmologyscience.org.

The neuropathic pain (NP) can be defined as a pain originated or induced by a cardinal disease or debilitation of the nervous system.^{1,2} The most prominent symptoms of NP are related to sensory abnormalities such as allodynia and hyperalgesia.³ There is various affirmation of pharmacologic therapy for the treatment of NP, but treatment is complicated and usually inadequate or involves unavoidable side effects. The potency of nonpharmacologic noninterventional therapy is also indistinct and vague.^{4–6} When NP involves the cornea of eye, it is called neuropathic corneal pain (NCP).^{7–11} The cornea of eye is the highly diverse vitalized tissue in the body dispensed by the ciliary nerve, which is the terminal branches of the trigeminal nerve's ophthalmic division (V1).^{12–15} Corneal nerves are

responsible for the maintenance and control of corneal sensitivity, epithelial integrity, proliferation, and injury repair.^{12,16,17} The NCP solution pathway or expected solution is inexplicit and blurry.^{2,7–9} The different causes of NCP consist of peripheral nerve and systemic diseases. Some of the various peripheral nerve diseases are dry eye disease, infectious keratitis, herpetic keratitis, refractive surgery, and cataract surgery, whereas the different systemic diseases involved are polyneuropathy, fibromyalgia, trigeminal neuralgia, autoimmune diseases, and diabetes. Additionally, underlying causes are anxiety, depression, and posttraumatic stress disorders.^{8–10,18–20} The chief symptoms of NCP are pain, dysesthesias (hyperalgesia), discomfort, photo allodynia, burning, irritation, dryness, and grittiness.^{18,20,21}

The mechanisms behind the pathophysiology of NCP involve sensory neurons, neural pathways, and the sensory cortex. The receptors necessary for pain apprehension and recognition are called nociceptors.^{2,22} These nociceptors readily respond to mechanical, chemical, thermal, and polymodal stimuli and give rise to action potentials.^{2,23} These different types of nociceptor stimulants are linked principally to the upper commanding somatosensory pain channel and the thalamus, both of which are the major pain matrices of the nervous system. In the course of functional stability, sensory neurons recognize different stimulants and give rise to physiological pain feedback and also defense tissues in distinction to intense offense.^{2,24} These phenomena contribute to dysfunction in peripheral axons, leading to the release of proinflammatory mediators.^{2,25,26} This entire process creates exaggeration of peripheral nerve sensation leading to augmented signals of peripheral pain known as peripheral sensitization. Moreover, this peripheral sensitization is converted into central sensitization when central neurons set off the same enormity of pain and tremendously intensify pain sensation.^{2,27–29} The consequence of these overall sensitization displays allodynia (pain due to a stimulus that does not usually provoke pain) and hyperalgesia (increased pain from a stimulus that usually provokes pain),^{2,30} and mostly, the pain becomes chronic. The profound effects of chronic pain are endured by millions of individuals and their families. Standard pharmacologic treatments for severe chronic pain often depend on the use of opioids.^{31,32}

On the grounds of clinical history, signs, prodrome, ophthalmic inspection, and proof of nerve damage, the investigation of NCP can be well validating. Currently, the different types of NCP treatment available are first-line topical therapy such as neurodegenerative and anti-inflammatory agents and first-line systemic pharmacotherapy such as tricyclic antidepressants and anticonvulsants. Then, there are second-line oral therapies such as opioid antagonists and opiate analgesics. Additionally, there are some complementary therapies also available such as cardiovascular exercise, acupuncture, and some kinds of supplements.² The pharmacologic side effects during NCP therapy cannot be neglected (Table 1).² Some adverse effects of these drugs are dry mouth, constipation sedation, peripheral edema, and sleep disturbances.^{2,5,25,26,37–41} Moreover, these different therapeutic strategies of NCP are not enough and also not well established because whether the aforementioned therapy will be appropriate or not, it cannot be predicted due to the utmost demanding testing nature of NCP disease.^{2,9,10,21} Therefore, the requirement of a new treatment strategy for NCP cannot be avoided.²

Photobiomodulation (PBM) is the practice of using light in response to stimulate tissue repair and reduce inflammation.^{42,43} The overall mechanisms involved in PBM are related to cytochrome c oxidase chromophores having heme and copper, although near infrared region is the spectrum of light wavelength where absorption takes place. Thereafter, the rising of membrane mitochondrial potential and adenosine triphosphate production takes

place due to the dissociation of inhibitory nitric oxide.⁴² The final results are an increase in cellular proliferation, migration, and adhesion while inhibiting apoptosis. Therefore, cell survival increases, whereas cell death decreases.⁴⁴ Photobiomodulation is a noninvasive procedure. The various implementations and uses of PBM are related from pain assurance to improvement of various inflammatory diseases such as tendinopathies or osteoarthritis and different nerve injury lesions.^{42,45–49} Photobiomodulation has been increasingly recognized as a safe and noninvasive therapeutic approach with a wide safety margin when applied correctly. Photobiomodulation typically uses low-level light in the red to near-infrared spectrum, which, unlike higher-intensity laser treatments, does not generate significant heat or cause tissue damage, minimizing the risk of adverse side effects.^{43,44,50} Previously, there were studies done on peripheral nerves related to its regeneration or recovery,⁵¹ but regarding NCP treatment, there is no PBM therapy until now (Table 2). Therefore, the aim of our research is to show the tissue repair aspect of PBM because of its biostimulation mechanism on the cornea of eye so that a novel treatment can be established in the medical field to treat NCP. We hypothesize that PBM will significantly reduce pain responses in animal models of NCP, with the extent of pain relief correlating with nerve injury and early intervention with PBM.

Methods

Animals

Animal handling procedures were performed in compliance with the guidelines set by the Institutional Animal Care and Use Committee of the Gwangju Institute of Science and Technology, South Korea. The animal experimental protocol (Protocol Number: GIST-2021-036) received approval from the Laboratory Animal Resource Center at the Gwangju Institute of Science and Technology. The study used Thy1-YFP transgenic mice (Stock No: 003709, Jackson Laboratory), aged 8–9 weeks with body weights ranging from 20 to 25 g. These mice were housed in the Laboratory Animal Resource Center and maintained under a 12-hour light/dark cycle, with ad libitum to food and water.

Animal Surgery

The animals were divided into 2 groups: no PBM and PBM group, having 4 animal models in each group (normal control [NC], sham control [SC], pulled nerve [PN], and full transection [FT]). The NCP was induced in both groups using established methods such as FT (to induce corneal denervation and explore mechanisms of NP: this model enables a controlled examination of the efficacy of PBM in promoting nerve repair and mitigating the impact of nerve injury on corneal health) of ciliary nerve and innovative methods such as the holding of ciliary nerve, that is, PN model. The animals were anesthetized with an intraperitoneal injection of a Zoletil/Rompun mixture in saline solution (60/10 mg/kg body weight). Anesthesia was confirmed using the tail pinch method. To prevent the eyes from drying, Neodex ophthalmic ointment (Hanlim Pharmaceuticals) was applied. The periorbital area was then shaved and disinfected with povidone iodine. A 1.5-mm lateral canthotomy was performed.¹² Using Vannas scissors and conjunctival forceps, an incision was made at the lateral conjunctival fornix at

Table 1. Current Treatment of NCP

Treatment Options	Description	Insights	References
Topical therapeutic eye drops including topical corticosteroids, blood-derived tear preparations, topical lacosamide, and low-dose naltrexone.	Anti-inflammatory, promotes corneal epithelial cell health, decreases hyper excitability of corneal cold-sensitive nerve terminals.	Longitudinal comparative studies demonstrating needs of the most effective topical treatment strategies.	Nortey et al (2022) ³³
A. Eye drops: -Autologous serum tears -Low-dose anti-inflammatory steroids	-May provide lubrication and promote healing. -Reduce inflammation and pain.	Eye drops made from the patient's own blood but require careful monitoring due to potential side effects.	Dieckmann et al ²
B. Systemic medications: TCAs: amitriptyline and nortriptyline -Calcium channel $\alpha_2\text{-}\delta$ ligands: gabapentin and pregabalin	-Can also help manage pain by modulating neurotransmitter release. -Can help modulate pain signals.		
C. Other therapies: Neurostimulation techniques such as TMS	-May offer pain relief.		
A. Artificial tears: lubricate the eye	-Relieve dry eye symptoms.	No single therapeutic approach or drug is satisfactory for the treatment of NCP. However, the use of autologous serum tears is mentioned as providing the highest likelihood of success.	Goyal et al (2016) ³⁴
B. Topical and systemic antibiotics: treat underlying conditions such as blepharitis	-Offer pain relief.		Aggarwal et al (2019) ³⁵
C. Scleral lenses: special contact lenses that vault over the cornea	-Reduce irritation and pain.		
Corneal neurotization (CN) -CN is a surgical reinnervation of the cornea where a normally functioning nerve or an interposition graft is placed.	-An improvement of corneal sensibility, visual acuity, and corneal integrity.	An extensive and time consuming surgery that requires a multidisciplinary approach.	Saad et al (2023) ³⁶

This table depicts the current treatment approach for NCP, which presents a significant challenge in clinical management. Effective management strategies include pharmacologic interventions, such as topical analgesics and systemic medications, and nonpharmacologic modalities, such as nerve blocks and neuromodulation techniques.

NCP = neuropathic corneal pain; TCAs = tricyclic antidepressants; TMS = transcranial magnetic stimulation.

a 90° angle, taking care to avoid the retro-orbital venous plexus. The eye was rotated nasally, and the muscles and soft and connective tissues were prepared using conjunctival forceps. The long ciliary nerve, branching from the trigeminal nerve, was identified approximately 0.3–0.4 mm from the exposed optic nerve. The study included 3 groups of animals: FT group, PN group, and SC group. Surgeries were conducted on the right eye of each animal. In the FT group, a ClearCut Sideport knife (dual bevel, 1 mm angled, Alcon #8065921540) was used to transect the ciliary nerve, with the eye globe rotated using the optic nerve as a landmark. In the PN group, the ciliary nerve was gently lifted about 2–3 mm vertically with an iris spatula (Barraquer, 0.5 mm, Katena, K 3-2300) for 10 seconds, applying gentle force ($\sim 0.09 \pm 0.02$ N) and pressure ($\sim 0.18 \pm 0.05$ MPa). The SC group underwent all procedures except the nerve injury steps. Incisions were closed with 6–0 Vicryl sutures, a drop of iodine solution was applied to prevent infection, and postoperative care included placing the animals on a heating pad.

Corneal Mechanical Sensitivity

Mechanical sensitivity of the cornea was evaluated by applying different forces to the corneal center in immobilized mice using calibrated von Frey (VF) filaments ranging from 0.008 to 0.16 g.^{57–59} The mechanical stimulation threshold was determined by recording the eye-blink response when the VF filament was applied with pressure for 5 seconds. All experimental procedures were performed by the same experimenter to maintain consistency, and the experiments were conducted under single-blind conditions, meaning that the experimenter was unaware of the group assignments.

Corneal Chemical Sensitivity

To assess the chemical sensitivity of the cornea, the eye-wiping test (EWT) was conducted both before and after surgery to determine the stimulation threshold. Ten microliters of a hypertonic NaCl solution (2M) were applied to the right eye of the mouse, which was then placed in an individual cage. The number of eye wipes using the forelimbs was counted over a 30-second period.^{59,60} Normal facial grooming and wipes of the contralateral eye were excluded from the count. All experimental procedures were carried out by the same experimenter under single-blind conditions to ensure consistency and reduce bias.

PBM Illumination

The PBM group received corneal illumination with a specific wavelength 808 nm (Uniotech, MDL-III-808R infrared diode laser), continuous wave, power 30 mW and radiant exposure (3.6 J/cm²) for a duration of 1 minute per session (once a day from D1 to D7) on the anesthetized mice.

Immunofluorescence Staining and Imaging

Corneas were harvested on D15 postsurgery (n = 6, each model group). For visualization and analysis, the corneas were fixed in 4% paraformaldehyde for 2 hours at 4° C. After fixation, the samples were washed several times with PBS. For whole-mount immunofluorescence staining, the samples were blocked with 5% goat or donkey serum in 0.3% Triton-X 100 in PBS for 2 hours at room temperature. The samples were then incubated overnight at 4° C with the indicated primary antibodies diluted in the blocking solution. After several washes with Triton-X 100 in PBS, the

Table 2. Photobiomodulation In Vivo Animal Model Name and Disease Treatment

Study	Animal Model	Light Parameters (Wavelength, Irradiance, and Dose)	Target Condition	Outcome	References
Safety and efficacy of 670 nm PBM for treatment of DME	Mice, rats, and human	Mice: 670 nm, 40 mW/cm ² for 90 sec/cycle, 2 cycles/day for 9 days. Rat: 670 nm, 100 or 500 mW/cm ² every 2 days for 1 wk. Human: 670 nm, 25, 100 or 200 mW/cm ² , 12 session over 5 wks	DME	Enhanced mitochondrial function and protected against oxidative stress, reduced retinal vascular leakage, reduction in CMT.	Shen et al (2020) ⁵²
Investigating the effect of PBM on corneal alkali burn injury	Rats	830 nm, 2 min, 5 mW/cm ² , once a day for 3 wks	Corneal alkali burn injury	Faster wound healing, enhance neovascularization, and modulate the expression of inflammatory cytokines.	Kim et al (2024) ⁵³
Evaluation of healing strategies in corneal opacity model	Rats	Polychromatic light in the NIR (600–1200 nm), 4.6 J/cm ² , 2 session/ week	Corneal opacity (mechanical injury)	Alleviated the inflammatory response and significantly decreased scar formation.	Uysal et al (2024) ⁵⁴
To elucidate 808 nm HECV	In vitro (HECV from umbilical vein)	808 nm, single dose 60 sec, 60 J/cm ²	In vitro cultured endothelial cells	A shift from anaerobic to aerobic metabolism, increase in O ₂ consumption and the ATP synthesis.	Amaroli et al (2019) ⁵⁵
Effects of 740 nm on DED in vivo	Mice	740 nm, 0.9 J/cm ² , 60 sec, total of 5 times in 17 days	DED	Tear volume increased, and corneal surface irregularities restored. Neutrophils and inflammatory cytokines decreased.	Goo et al (2019) ⁵⁶

This table illustrates the in vivo animal models used for studying disease treatment, particularly CP, and the role of PBM in these models. Despite the widespread application of PBM in various preclinical models of pain, its utilization in NCP animal models remains unsolved. This table highlights the need for further research to explore the potential therapeutic effects of PBM in NCP animal models, which could provide valuable insights into its efficacy and mechanism of action in treating this challenging condition.

ATP = adenosine triphosphate; CMT = central macular thickness; CP = corneal pain; DED = dry eye disease; DME = diabetic macular edema; HECV = human endothelial cells; NCP = neuropathic corneal pain; NIR = near infrared; PBM = photobiomodulation.

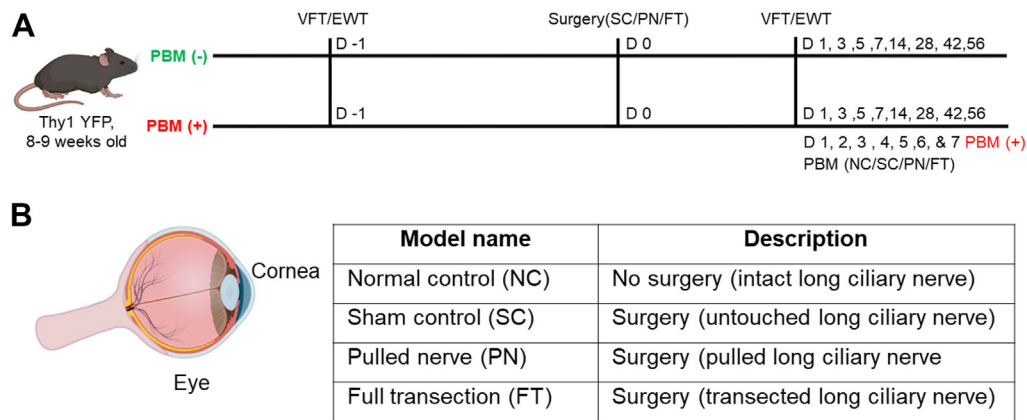


Figure 1. Schematic overview of experimental design for PBM in neuropathic corneal pain models. **A**, Provides a comprehensive schematic of the experimental timeline used to evaluate the effects of PBM on various corneal nerve injury models. The models included are NC, SC, PN, and FT. This shows a timeline of the VFT and EWT conducted across multiple postoperative days (day -1, day 0, day 1, day 3, day 5, day 7, day 14, day 28, day 42, and day 56). In addition, the application schedule of PBM, administered once daily from day 1 to 7, highlights the distinction between PBM-treated and nontreated groups. **B**, Sets the experimental foundation, describing the models' names and corresponding descriptions, outlining the specific nerve manipulations (intact, untouched, pulled, and transected). EWT = eye-wiping test; FT = full transection; NC = normal control; PBM = photobiomodulation; PN = pulled nerve; SC = sham control; VFT = von Frey test.

samples were incubated for 2 hours at room temperature with the indicated fluorochrome-conjugated secondary antibodies, also diluted in the blocking buffer. After additional washes with Triton-X 100 in PBS, the samples were mounted using a Vecta-shield (Vector Laboratories) fluorescence mounting medium. The primary and secondary antibodies used were as follows: anti- β tubulin (1:200, rabbit polyclonal, ab18207, Abcam) and Alexa 488-conjugated secondary antibodies (1:1000, Invitrogen) respectively. Images were obtained using an LSM 800 confocal microscope (Carl Zeiss) and processed with ZEN (Zeiss) imaging software from the subepithelial nerve plexus in the peripheral regions.

Statistical Analysis

The results are presented as mean \pm standard deviation. Data analysis was performed using GraphPad Prism 9 (GraphPad Software). Changes in mechanical and chemical corneal sensitivities before and after surgery in the ipsilateral eye were assessed using a paired *t* test within each group and a Student *t* test to compare differences between the no PBM and PBM groups. Differences in corneal nerve density between the no PBM and PBM groups were evaluated using a Student *t* test. Each experimental model comprised 5 animals ($n = 5$), and each group had 10 animals ($n = 10$).

Results

Experimental Design and Timeline for PBM Treatment in NCP Models

The experimental setup involves measuring mechanical sensitivity through the VF test (VFT) and chemical sensitivity through the EWT on NC, SC, PN, and FT models of NCP. Measurements were taken 1 day before surgery (D-1) and on days 1, 3, 5, 7, 14, 28, 42, and 56 postsurgeries. The PBM group received PBM treatment for 1 minute daily from day 1 to 7 postsurgery (Fig 1A). Figure 1B illustrates the

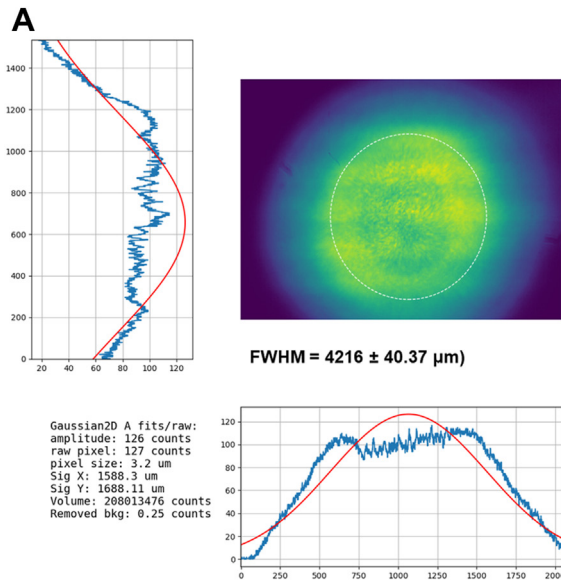
surgical techniques employed to induce NCP in animal models, highlighting the variants used for studying the efficacy of PBM. Each variant is tailored to replicate different levels of nerve injury (Fig S1, available at www.opthalmologyscience.org), allowing for a comprehensive evaluation of PBMs therapeutic potential in mitigating NCP.

Beam Profile Analysis in PBM and Parameters of the PBM Laser Treatment

Figure 2A presents the analysis of laser beam profiles used in PBM therapy, highlighting their critical role in determining the treatment's efficacy and safety in NCP models. The full-width at half-maximum for the laser beam is also provided ($4216 \pm 40.37 \mu\text{m}$). Figure 2B details the specific laser parameters used during the PBM therapy sessions applied to the corneal nerve injury models. Key parameters for initiating PBM therapy were established, including output wavelength (808 nm), continuous wave mode, irradiance (0.06 W/cm^2), radiant exposure (3.6 J/cm^2), and power (30 mW). Photobiomodulation was applied obliquely over the eye (Fig S2, available at www.opthalmologyscience.org). Photobiomodulation was administered daily from day 1 to 7, ensuring consistent treatment across the experimental period (Fig S3, available at www.opthalmologyscience.org).

Assessment of PBM Through VF Filament test in NCP Models

A detailed schematic illustrates the VFT procedure, where calibrated VF filaments (0.008–0.16 g) were applied for 5 seconds to assess mechanical sensitivity, indicating the setup and procedure used to measure mechanical allodynia and hyperalgesia (Fig 3A). Behavioral testing results were compared between PBM and no PBM groups for



B

PBM Laser Parameters	
Output wavelength (nm)	808
Working mode	Continuous wave
Irradiance (W/cm^2)	$0.06 \text{ W} / \text{cm}^2$
Radiant exposure (J/cm^2)	$3.6 \text{ J} / \text{cm}^2$
Exposure interval	60 s
Power (mW)	30 mW
Mode of PBM application	Over the eye at an oblique angle
Irradiation treatment	Once a day (daily from D1 to D7)
Spot area (cm^2)	0.5

Figure 2. Analysis of beam profiles in PBM and parameters of the laser treatment in PBM and used in this study. **A**, Displays the beam profile of the PBM laser, illustrating the distribution of light intensity across the treatment area. The uniformity of the beam ensures consistent delivery of therapeutic energy to the corneal tissue. **B**, Details the specific laser parameters used during the PBM therapy sessions applied to the corneal nerve injury models, the laser's output wavelength (808 nm), working mode (continuous wave), irradiance ($0.06 \text{ W}/\text{cm}^2$), radiant exposure ($3.6 \text{ J}/\text{cm}^2$), exposure interval (60 seconds), and power output (30 mW). The laser was applied over the eye at an oblique angle with a spot area of 0.5 cm^2 . FWHM = full width half maximum; PBM = photobiomodulation.

NC, SC, PN, and FT models. The corneal mechanical sensitivity threshold was measured using VF filaments from D-1 to D56 postsurgery. Baseline mechanical sensitivity was established, providing a reference for comparing other groups using the NC and SC models. There were no significant changes in both NC (Fig 3B) and SC (Fig 3C) models after the application of PBM therapy. The average behavioral test values from day 1 to 56 were compared between the no PBM (NC: D1 = 0.15 ± 0.014 , D3 = 0.15 ± 0.014 , D5 = 0.14 ± 0.014 , D7 = 0.14 ± 0.012 , D14 = 0.15 ± 0.014 , D28 = 0.15 ± 0.014 , D42 = 0.13 ± 0.02 , D56 = 0.13 ± 0.016 . SC: D1 = 0.11 ± 0.009 , D3 = 0.11 ± 0.012 , D5 = $0.11 \pm$

0.014 , D7 = 0.12 ± 0.004 , D14 = 0.11 ± 0.012 , D28 = 0.12 ± 0.012 , D42 = 0.13 ± 0.02 , D56 = 0.11 ± 0.009) and PBM (NC: D1 = 0.15 ± 0.009 , D3 = 0.15 ± 0.014 , D5 = 0.14 ± 0.012 , D7 = 0.14 ± 0.012 , D14 = 0.15 ± 0.012 , D28 = 0.15 ± 0.014 , D42 = 0.13 ± 0.01 , D56 = 0.14 ± 0.014 . SC: D1 = 0.12 ± 0.014 , D3 = 0.12 ± 0.014 , D5 = 0.12 ± 0.014 , D7 = 0.12 ± 0.004 , D14 = 0.12 ± 0.004 , D28 = 0.15 ± 0.014 , D42 = 0.14 ± 0.014 , D56 = 0.12 ± 0.004) groups. In the PN model, the mechanical stimulation threshold that elicited an eye-blink response increased significantly post-PBM treatment (Fig 3D). The average behavioral test values from day 1 to 56 between no PBM (D1 = $0.043 \pm$

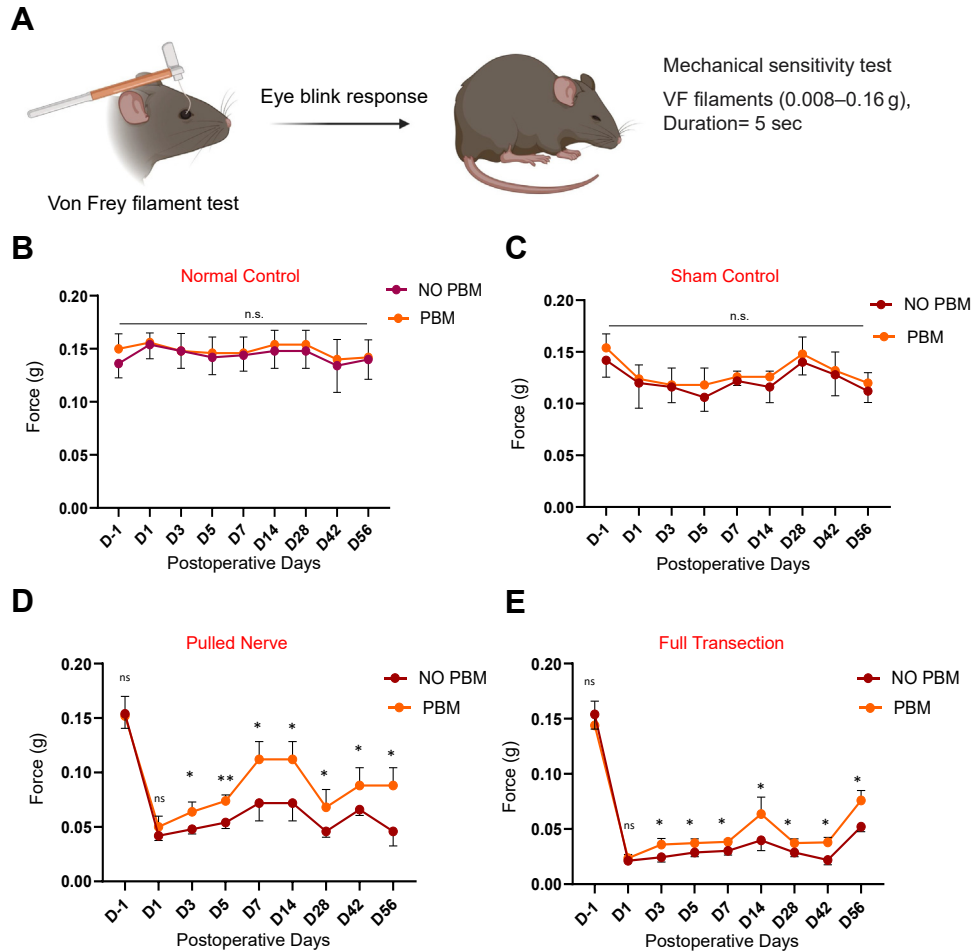


Figure 3. Mechanical sensitivity outcomes in NCP models assessed by VFT. **A**, Schematic representation of the VFT. This schematic diagram illustrates the setup and procedure of the mechanical test, commonly used to assess mechanical allodynia and hyperalgesia in rodent models of NCP, which shows the force (g) required to elicit an eye-blink response in each model (NC, SC, PN, and FT) at various time points. **B–E**, Present the results of the mechanical sensitivity tests conducted using VF filaments across different postoperative days (day -1, day 1, day 3, day 5, day 7, day 14, day 28, day 42, and day 56) in each model (NC, SC, PN, and FT). There were 2 groups: PBM and no PBM group. A comparative analysis of mechanical sensitivity between PBM-treated and nontreated groups was performed. The corneal mechanical sensitivity threshold (g) of ipsilateral eye (before and after surgery) for NC, SC, PN, and FT was measured using VF filaments. Results are expressed as the mean (\pm SD) from D-1 to D56 postsurgery ($n = 5$ in each group, total $n = 10$ in each model). *Statistically significant difference: * $P < 0.05$, ** $P < 0.01$, ns = no significant. FT = full transection; NC = normal control; NCP = neuropathic corneal pain; PBM = photobiomodulation; PN = pulled nerve; SC = sham control; SD = standard deviation; VF = von Frey; VFT = von Frey test.

0.044, D3 = 0.046 ± 0.044 , D5 = 0.053 ± 0.0047 , D7 = 0.076 ± 0.016 , D14 = 0.076 ± 0.016 , D28 = 0.046 ± 0.004 , D42 = 0.06 ± 0.004 , D56 = 0.05 ± 0.014) and PBM (D1 = 0.050 ± 0.008 , D3 = 0.066 ± 0.009 , D5 = 0.073 ± 0.0047 , D7 = 0.11 ± 0.014 , D14 = 0.11 ± 0.014 , D28 = 0.07 ± 0.014 , D42 = 0.09 ± 0.014 , D56 = 0.09 ± 0.014) groups were calculated. Similarly, the FT model demonstrated a substantial increase in the mechanical stimulation threshold after PBM (Fig 3E). The average behavioral test values from day 1 to 56 between no PBM (D1 = 0.022 ± 0.0028 , D3 = 0.025 ± 0.0041 , D5 = 0.028 ± 0.0033 , D7 = 0.030 ± 0.0033 , D14 = 0.038 ± 0.008 , D28 = 0.028 ± 0.0033 , D42 = 0.023 ± 0.0047 , D56 = 0.023 ± 0.0047) and PBM (D1 = 0.024 ± 0.0028 , D3 = 0.036 ± 0.0047 , D5 = 0.037 ± 0.0033 , D7 = 0.038 ± 0.0018 , D14 =

0.062 ± 0.012 , D28 = 0.037 ± 0.0033 , D42 = 0.036 ± 0.0047 , D56 = 0.073 ± 0.0094) groups were calculated.

Assessment of PBM Through EWT in NCP Models

The EWT was used to evaluate chemical corneal sensitivity by counting the number of eye wipes in response to a hypertonic NaCl solution (Fig 4A). There were no significant changes in both NC (Fig 4B) and SC (Fig 4C) models after the application of PBM therapy. The average behavioral test values from day 1 to 56 were compared between no PBM (NC: D1 = 9.96 ± 0.28 , D3 = 9.5 ± 0.82 , D5 = 9.06 ± 0.65 , D7 = 9.5 ± 0.14 , D14 = 9.53 ± 0.41 , D28 = 9.63 ± 0.47 , D42 = 9.63 ± 0.41 , D56 = 9.96 ± 0.41 . SC: D1 = 10.96 ± 0.69 , D3 = 11.4 ± 0.28 ,

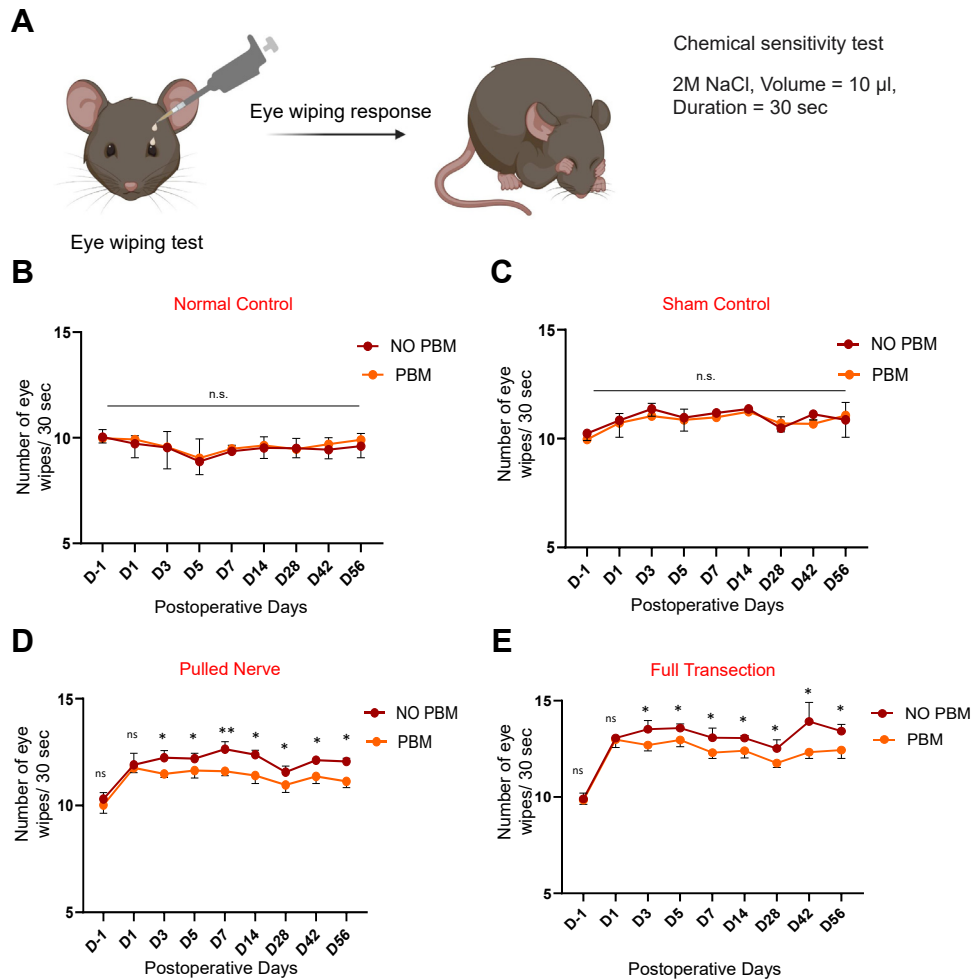


Figure 4. Chemical sensitivity outcomes in neuropathic corneal pain models assessed by EWT. **A**, Depicts the chemical sensitivity measured by the number of eye wipes performed in response to a 2M NaCl solution across different postoperative days in each model (NC, SC, PN, and FT) at various time points. **B–E**, Present the results of the chemical sensitivity tests conducted in response to a 2M NaCl solution across different postoperative days (day –1, day 1, day 3, day 5, day 7, day 14, day 28, day 42, day 56) in each model (NC, SC, PN, and FT). There were 2 groups: PBM and no PBM group. A comparative analysis of chemical sensitivity between PBM-treated and nontreated groups was performed. The corneal chemical sensitivity threshold (g) of ipsilateral eye (before and after surgery) for NC, SC, PN, and FT were measured using 2M NaCl solution. Results are expressed as the mean (\pm SD) from D-1 to D56 postsurgery ($n = 5$ in each group, total $n = 10$ in each model). *Statistically significant difference: $*P < 0.05$, $**P < 0.01$, ns = no significant. EWT = eye-wiping test; FT = full transection; NC = normal control; PBM = photobiomodulation; PN = pulled nerve; SC = sham control; SD = standard deviation.

D5 = 11.06 ± 0.55 , D7 = 11.2 ± 0.14 , D14 = 11.4 ± 0.41 , D28 = 10.5 ± 0.41 , D42 = 11.2 ± 0.28 , D56 = 10.99 ± 0.71) and PBM (NC: D1 = 9.66 ± 0.47 , D3 = 9.2 ± 0.94 , D5 = 8.86 ± 0.83 , D7 = 9.4 ± 0.14 , D14 = 9.53 ± 0.41 , D28 = 9.43 ± 0.47 , D42 = 9.63 ± 0.28 , D56 = 9.66 ± 0.47 . SC: D1 = 10.66 ± 0.47 , D3 = 10.86 ± 0.61 , D5 = 10.76 ± 0.55 , D7 = 11.06 ± 0.32 , D14 = 11.2 ± 0.14 , D28 = 10.63 ± 0.28 , D42 = 10.73 ± 0.18 , D56 = 10.88 ± 0.62) groups. For the PN model, the number of eye wipes decreased significantly after PBM treatment (Fig 4D). The average behavioral test values from day 1 to 56 were compared between no PBM (D1 = 11.96 ± 0.47 , D3 = 12.2 ± 0.28 , D5 = 12.26 ± 0.24 , D7 = 12.56 ± 0.32 , D14 = 12.36 ± 0.16 , D28 = 11.63

± 0.28 , D42 = 12.1 ± 0.14 , D56 = 12.11 ± 0.15) and PBM (D1 = 11.73 ± 0.18 , D3 = 11.5 ± 0.14 , D5 = 11.63 ± 0.28 , D7 = 11.6 ± 0.16 , D14 = 11.6 ± 0.33 , D28 = 10.96 ± 0.28 , D42 = 11.4 ± 0.28 , D56 = 11.22 ± 0.31) groups. The FT model also showed a significant reduction in eye-wiping behavior post-PBM (Fig 4E). The average behavioral test values from day 1 to 56 were compared between no PBM (D1 = 13.1 ± 0.14 , D3 = 13.43 ± 0.41 , D5 = 13.53 ± 0.20 , D7 = 13.06 ± 0.41 , D14 = 13.1 ± 0.14 , D28 = 12.43 ± 0.41 , D42 = 13.76 ± 0.88 , D56 = 13.36 ± 0.30) and PBM (D1 = 12.86 ± 0.41 , D3 = 11.63 ± 0.28 , D5 = 12.96 ± 0.28 , D7 = 12.3 ± 0.24 , D14 = 12.46 ± 0.33 , D28 = 12.73 ± 0.18 , D42 = 12.33 ± 0.26 , D56 = 12.53 ± 0.41) groups.

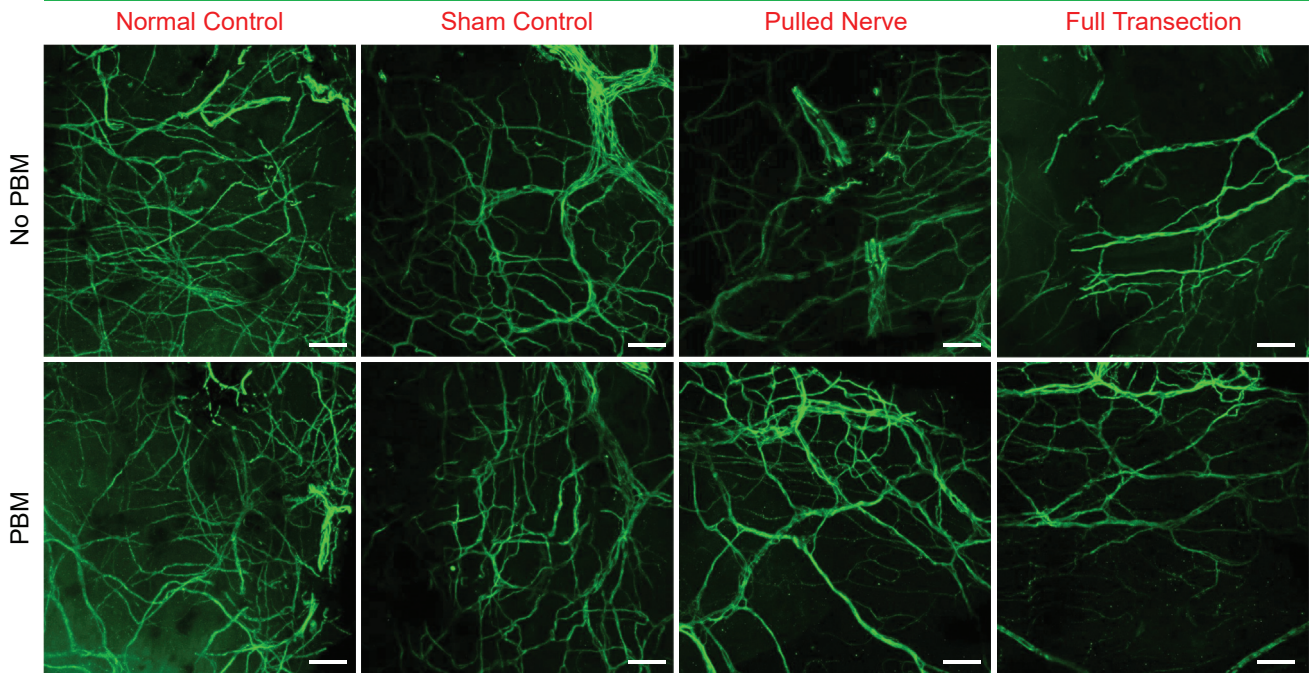
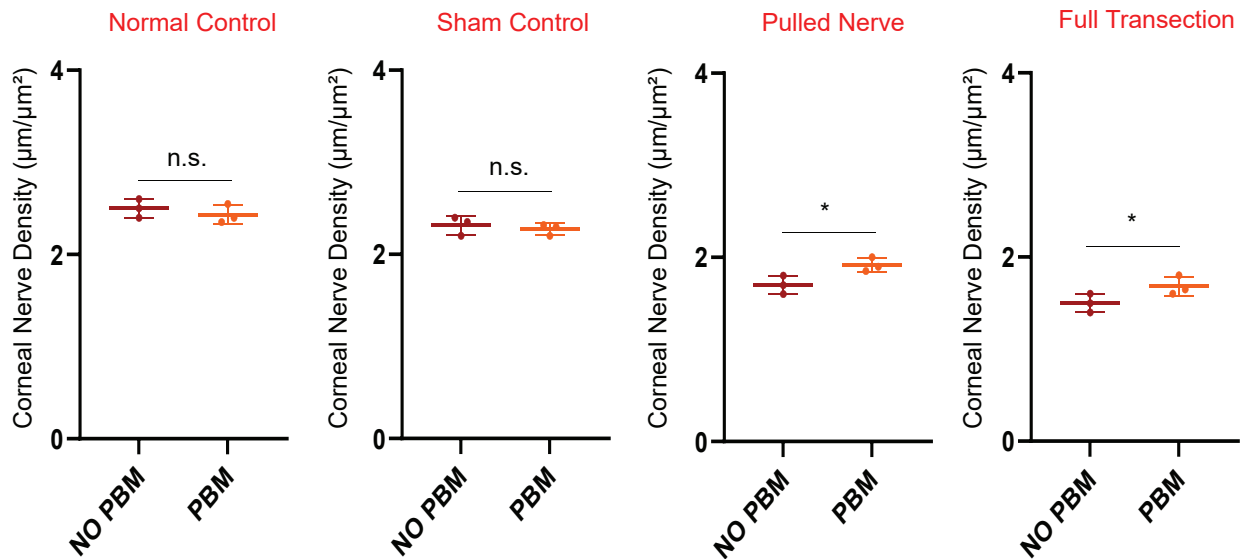
AAnti- β -tubulin**B**

Figure 5. A, Corneal nerve density and morphology visualized by anti- β -tubulin staining. Representative confocal images showing corneal nerve structures stained with anti- β -tubulin antibody across different experimental groups (NC/SC/PN/FT) on day 15 postsurgery (SC/PN/FT) obtained from the sub-epithelial nerve plexus in the peripheral regions (Fig S4, available at www.ophtalmologyscience.org). The fluorescence highlights nerve fibers, illustrating their branching patterns, density, and overall morphology. The upper panel corresponds to a no PBM group, whereas the lower panel corresponds to PBM group. Scale bars represent 50 μ m. B, A comparative analysis of corneal nerve density across experimental groups (NC/SC/PN/FT). This analysis provides quantitative insight into changes in corneal nerve density, with implications for understanding corneal NP mechanisms and therapeutic outcomes. Data points represent measurements from $n = 6$ mice in each model (no PBM $n = 3$ and PBM $n = 3$). Statistical significance is denoted as $*P < 0.05$, n.s. = not significant. FT = full transection; NC = normal control; PBM = photobiomodulation; PN = pulled nerve; SC = sham control.

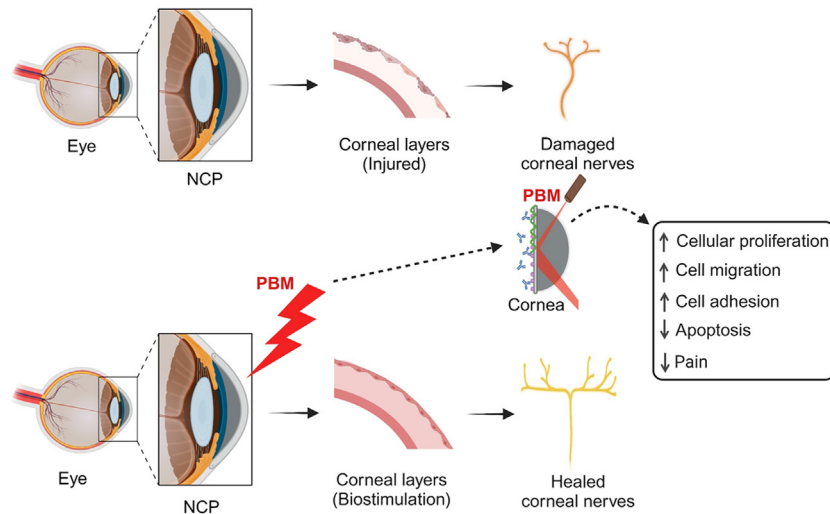


Figure 6. Exploring the therapeutic effects of PBM with insights into clinical applications through bio stimulation effects. Photobiomodulation has shown promising therapeutic effects in alleviating NP by modulating inflammatory responses and reducing neuronal hypersensitivity. Studies have demonstrated that PBM can enhance corneal nerve regeneration and improve corneal sensitivity, leading to reduced pain perception in patients. NCP = neuropathic corneal pain; NP = neuropathic pain; PBM = photobiomodulation.

PBM Enhances Corneal Nerve Density and Morphologic Integrity

In the NC group, anti- β tubulin staining of corneal nerves showed a dense, organized nerve architecture. These nerves displayed typical morphology, with clear expression confirming the structural integrity of the corneal nerve fibers (Fig 5A). The SC models exhibited a similar pattern, with no significant deviation in nerve density or morphology from the NC group. Photobiomodulation treatment in the NC and SC groups did not yield notable changes in nerve integrity, as nerve morphology and density were maintained (Fig 5B). In the PN model, β -tubulin staining revealed disrupted corneal nerve morphology compared with NC and SC (Fig 5A). Nerve fibers were visibly disorganized, with a decrease in branching and nerve density. With PBM treatment in the PN model, there was a notable improvement in corneal nerve morphology (Fig 5B). Anti- β tubulin staining indicated partial restoration of nerve density, with increased branching of nerve fibers compared with untreated PN models. In the FT model, β -tubulin staining revealed a pronounced loss of nerve structure, with marked reductions in nerve density and branching (Fig 5A). After PBM treatment in the FT model, β -tubulin staining revealed modest improvements in nerve structure, with notable increases in nerve density and a more organized arrangement of remaining fibers compared with untreated FT models (Fig 5B).

Discussion

The present study demonstrates that PBM significantly alleviates NCP in animal models, specifically in PN and FT models. Photobiomodulation, a noninvasive light therapy, has shown potential in neural repair and pain alleviation

through several cellular and molecular mechanisms. Photobiomodulation primarily acts by influencing mitochondrial function, where it enhances adenosine triphosphate production by stimulating cytochrome c oxidase in the electron transport chain. This increase in adenosine triphosphate boosts cellular energy, promoting repair processes in damaged neurons and improving cellular resilience in stressed tissue environments.⁶¹ Photobiomodulation decreases oxidative damage by increasing the activity of antioxidant enzymes such as superoxide dismutase⁶² and catalase, which neutralize reactive oxygen species that accumulate during injury and stress. This reduction in oxidative stress protects nerve cells from further damage, supporting overall neural health and recovery.⁶³ Furthermore, PBM was found to stimulate the expression of neurotrophic factors, including brain-derived neurotrophic factor and nerve growth factor, both essential for neuron survival, growth, and plasticity. The upregulation of these neurotrophic factors encourages neural repair and regeneration, facilitating recovery in injured nerve tissues.⁴² Through these mechanisms of mitochondrial function, reducing inflammation, lowering oxidative stress, and promoting neurotrophic factor expression, PBM contributes to both pain alleviation and neural repair, presenting a promising therapeutic approach for neurodegenerative diseases and nerve regeneration.⁶⁴

Photobiomodulation has been applied across numerous medical fields, with extensive research supporting its safety profile. Both preclinical and clinical studies consistently demonstrate an absence of adverse effects in short- and long-term use.⁶⁵ Long-term follow-up, spanning up to 15 years, has shown no adverse events or the development of secondary malignancies, particularly in PBM protocols for oral mucositis treatment.⁶⁶ A recent systematic review focusing on oncology also found no significant adverse

events or tumor-related safety issues when PBM was used to prevent and manage toxicities associated with chemotherapy and radiation.⁶⁷ In transcranial PBM applications, there have been no adverse events or histologic signs indicating biosafety concerns. Even after prolonged intracranial PBM device implantation, studies report no inflammatory glial response, neuronal degeneration, abnormal mitochondrial activity, or adverse effects on nearby blood vessels.⁶⁸

The VFT, which measures mechanical allodynia, showed a significant reduction in pain sensitivity in both the PN and FT models after PBM treatment. These findings are consistent with previous studies that have reported the analgesic effects of PBM in various animal models including pain.^{43,69} The effectiveness of PBM in the PN and FT models suggests that this therapy may be particularly beneficial for patients with NCP, where traditional pharmacologic treatments often fall short. The reduction in pain sensitivity observed in these models can be attributed to the anti-inflammatory and neuroprotective effects of PBM, which likely contribute to the stabilization and partial restoration of corneal nerve function. These findings are consistent with previous research indicating that PBM can promote nerve regeneration and reduce NP in other peripheral neuropathy models.^{70,71} The reduction in mechanical sensitivity indicates that PBM may modulate pain pathways at the peripheral nerve level, possibly by enhancing nerve repair and reducing inflammation.^{51,72} The drop in pain sensitivity at day 28 in the PN and FT models is likely due to nerve degeneration, improper axonal regeneration, and neuroplastic changes occurring during the recovery phase postinjury.^{73–77} These processes are absent in NC and SC models, which do not involve significant nerve injury, explaining the absence of a similar drop in those groups.

The EWT, used to assess chemical sensitivity and pain, also revealed significant improvements in the PBM-treated groups. Animals in the PN and FT models exhibited fewer eye wipes compared with their untreated counterparts, indicating reduced corneal pain. This reduction in pain behavior aligns with studies suggesting that PBM can decrease pain through anti-inflammatory effects and promotion of cellular repair mechanisms.^{42,78} The EWT revealed a decrease in chemically induced pain responses, further supporting the analgesic effects of PBM in these models.^{79,80} The results of this study demonstrate the potential of PBM as an effective therapeutic intervention for NCP management in mice. The findings from this study provide compelling evidence regarding the effects of PBM on corneal nerve integrity across different models of NCP, evaluated using anti- β tubulin staining. By

analyzing NC, SC, PN, and FT models, we have furthered the understanding of PBM's role in nerve preservation and regeneration, particularly in models mimicking neuropathic damage. Comparing the results across models underscores the nuanced effects of PBM in neural repair. In partially damaged nerves, such as in the PN model, PBM demonstrated substantial benefits, whereas in cases of complete transection, its impact was also not neglected. This differential response suggests that PBM could be strategically applied in clinical settings for conditions involving corneal nerve injury involving NP.

The specific timeline of experiments allowed for the evaluation of pain relief after PBM treatment. The differential responses to PBM across the models likely reflect the distinct underlying mechanisms of nerve injury in each case. In the PN and FT models, where nerve damage is more extensive, PBM may exert its effects through multiple pathways, including the reduction of inflammation, the promotion of nerve regeneration, and the modulation of pain signaling pathways. Further research is warranted to investigate the underlying mechanisms of PBM-induced pain relief and corneal nerve regeneration (Fig 6). This study contributes to the growing evidence supporting PBM as a promising approach for NCP management. As part of future work, the application of in vivo electrophysiological techniques to directly record nociceptor activity in our NCP models, both before and after surgery, would allow for real-time assessment of changes in pain-related neuronal activity, offering deeper insight into the functional impact of NCP and the efficacy of therapeutic interventions such as PBM.

The findings highlight the analgesic effects of PBM, as evidenced by the reduction in pain-related behaviors, and later provide insights into the regenerative properties of PBM in promoting corneal nerve recovery. The temporal analysis of PBM efficacy, conducted from day -1 (pre-surgery baseline) to day 56 postsurgery, provides valuable insights into the duration and progression of therapeutic effects. The temporal patterns also suggest that early intervention with PBM, initiated shortly after nerve injury, may be crucial for preventing the chronic progression of NCP. The early application of PBM might limit the extent of nerve damage and modulate the inflammatory response, thereby reducing the likelihood of developing chronic pain.

Acknowledgments

The authors like to thank Christine H. Hwang and An Nazmus Sakib Galib for their assistance with the behavioral tests.

Footnotes and Disclosures

Originally received: August 14, 2024.

Final revision: December 3, 2024.

Accepted: December 12, 2024.

Available online: December 18, 2024. Manuscript no.: XOPS-D-24-00297R2.

¹ Department of Biomedical Science and Engineering, Gwangju Institute of Science and Technology, Gwangju, South Korea.

² Department of Radiology, Harvard Medical School, Boston, Massachusetts.

³ AI Graduate School, Gwangju Institute of Science and Technology, Gwangju, South Korea.

Disclosure(s):

All authors have completed and submitted the ICMJE disclosures form.

The author(s) have no proprietary or commercial interest in any materials discussed in this article.

Supported by the AI-based GIST Research Scientist Project grant funded by the GIST in 2024, the National Research Foundation of Korea (NRF) grant funded by the Korea government (MSIT) (grants RS-2023-00264409, RS-2023-00302281), and the Brain Pool program funded by the Ministry of Science and ICT through the NRF of Korea (grant RS-2023-00304323). Support for open access publication was provided by the Gwangju Institute of Science and Technology.

HUMAN SUBJECTS: No human subjects were included in this study.

Animal subjects were used in this study. Animal handling procedures were performed in compliance with the guidelines set by the Institutional Animal Care and Use Committee (IACUC) of the Gwangju Institute of Science and Technology (GIST), South Korea. The animal experimental protocol (Protocol Number: GIST161 2021-036) received approval from the Laboratory Animal Resource Center (LARC) at GIST.

Author Contributions:

Conception and design: Khan, Chung

Data collection: Khan

Analysis and interpretation: Khan

Obtained funding: N/A

Overall responsibility: Khan, Fatima, Ashiquzzaman, S.S. Kim, Kwon, Y.R. Kim

Abbreviations and Acronyms:

EWT = eye-wiping test; **FT** = full transection; **NC** = normal control; **NCP** = neuropathic corneal pain; **NP** = neuropathic pain; **PBM** = photobiomodulation; **PN** = pulled nerve; **SC** = sham control; **VF** = von Frey; **VFT** = von Frey test.

Keywords:

Behavior tests, Chronic pain, Invivo, Neuropathic corneal pain (NCP), Photobiomodulation (PBM).

Correspondence:

Euiheon Chung, PhD, Department of Biomedical Science and Engineering, AI Graduate School, Gwangju Institute of Science and Technology, 123 Cheomdan-wagiro, Buk-gu, Gwangju 61005, South Korea. E-mail: ogong50@gist.ac.kr.

References

1. Dworkin RH, O'Connor AB, Kent J, et al. Interventional management of neuropathic pain: NeuPSIG recommendations. *Pain*. 2013;154:2249–2261.
2. Dieckmann G, Goyal S, Hamrah P. Neuropathic corneal pain: approaches for management. *Ophthalmology*. 2017;124:S34–S47.
3. Greenspan JD. Quantitative assessment of neuropathic pain. *Curr Pain Headache Rep*. 2001;5:107–113.
4. Attal N, Cruccu G, Haanpää M, et al. EFNS guidelines on pharmacological treatment of neuropathic pain. *Eur J Neurol*. 2006;13:1153–1169.
5. Dworkin RH, O'Connor AB, Backonja M, et al. Pharmacologic management of neuropathic pain: evidence-based recommendations. *Pain*. 2007;132:237–251.
6. Moulin DE, Clark AJ, Gilron I, et al. Pharmacological management of chronic neuropathic pain-consensus statement and guidelines from the Canadian Pain Society. *Pain Res Manag*. 2007;12:13–21.
7. Rosenthal P, Borsook D. The corneal pain system. Part I: the missing piece of the dry eye puzzle. *Ocul Surf*. 2012;10:2–14.
8. Rosenthal P, Borsook D. Ocular neuropathic pain. *Br J Ophthalmol*. 2016;100:128–134.
9. Rosenthal P, Borsook D, Moulton EA. Oculofacial pain: corneal nerve damage leading to pain beyond the eye. *Invest Ophthalmol Vis Sci*. 2016;57:5285–5287.
10. Aggarwal S, Kheirkhah A, Cavalcanti BM, et al. Autologous serum tears for treatment of photoallodynia in patients with corneal neuropathy: efficacy and evaluation with in vivo confocal microscopy. *Ocul Surf*. 2015;13:250–262.
11. Hamrah P, Qazi Y, Shahatit B, et al. Corneal nerve and epithelial cell alterations in corneal allodynia: an in vivo confocal microscopy case series. *Ocul Surf*. 2017;15:139–151.
12. Yamaguchi T, Turhan A, Harris DL, et al. Bilateral nerve alterations in a unilateral experimental neurotrophic keratopathy model: a lateral conjunctival approach for trigeminal axotomy. *PLOS One*. 2013;8:e70908.
13. Müller LJ, Pels L, Vriens G. Ultrastructural organization of human corneal nerves. *Invest Ophthalmol Vis Sci*. 1996;37:476–488.
14. Belmonte C, Acosta MC, Gallar J. Neural basis of sensation in intact and injured corneas. *Exp Eye Res*. 2004;78:513–525.
15. Gallar J, Pozo MA, Rebollo I, Belmonte C. Effects of capsaicin on corneal wound healing. *Invest Ophthalmol Vis Sci*. 1990;31:1968–1974.
16. Garcia-Hirschfeld J, Lopez-Briones LG, Belmonte C. Neurotrophic influences on corneal epithelial cells. *Exp Eye Res*. 1994;59:597–605.
17. Belmonte C, Giraldez F. Responses of cat corneal sensory receptors to mechanical and thermal stimulation. *J Physiol*. 1981;321:355–368.
18. Galor A, Levitt RC, Felix ER, Sarantopoulos CD. Understanding the true burden of dry eye disease. *Exp Rev Ophthalmol*. 2015;10:403–405.
19. Crane AM, Levitt RC, Felix ER, et al. Patients with more severe symptoms of neuropathic ocular pain report more frequent and severe chronic overlapping pain conditions and psychiatric disease. *Br J Ophthalmol*. 2017;101:227–231.
20. Theophanous C, Jacobs DS, Hamrah P. Corneal neuralgia after LASIK. *Optom Vis Sci*. 2015;92:e233–e240.
21. Galor A, Levitt RC, Felix ER, et al. Neuropathic ocular pain: an important yet undervalued feature of dry eye. *Eye*. 2015;29:301–312.
22. Lee Y, Lee C-H, Oh U. Painful channels in sensory neurons. *Mol Cells*. 2005;20:315–324.
23. Brooks J, Tracey I. From nociception to pain perception: imaging the spinal and supraspinal pathways. *J Anat*. 2005;207:19–33.
24. Belmonte C, Acosta M, Merayo-Llones J, Gallar J. What causes eye pain? *Curr Ophthalmol Rep*. 2015;3:111–121.
25. Jensen TS, Madsen CS, Finnerup NB. Pharmacology and treatment of neuropathic pains. *Curr Opin Neurol*. 2009;22:467–474.
26. Panlilio LM, Christo PJ, Raja SN. Current management of postherpetic neuralgia. *Neurologist*. 2002;8:339–350.
27. Oprea A, Kress M. Involvement of the proinflammatory cytokines tumor necrosis factor- α , IL-1 β , and IL-6 but not IL-8 in the development of heat hyperalgesia: effects on heat-evoked calcitonin gene-related peptide release from rat skin. *J Neurosci*. 2000;20:6289–6293.

28. Lin C-R, Amaya F, Barrett L, et al. Prostaglandin E2 receptor EP4 contributes to inflammatory pain hypersensitivity. *J Pharmacol Exp Ther*. 2006;319:1096–1103.
29. Hains BC, Saab CY, Klein JP, et al. Altered sodium channel expression in second-order spinal sensory neurons contributes to pain after peripheral nerve injury. *J Neurosci*. 2004;24:4832–4839.
30. Louw A, Nijs J, Puentedura EJ. A clinical perspective on a pain neuroscience education approach to manual therapy. *J Man Manip Ther*. 2017;25:160–168.
31. Malafoglia V, Ilari S, Vitiello L, et al. The interplay between chronic pain, opioids, and the immune system. *Neuroscientist*. 2022;28:613–627.
32. Buzza AS, Cousins H, Tapas KE, et al. Direct photobiomodulation therapy on the sciatic nerve significantly attenuates acute nociceptive sensitivity without affecting motor output. *Neuromodulation*. 2024;27:1338–1346.
33. Nortey J, Smith D, Seitzman GD, Gonzales JA. Topical therapeutic options in corneal neuropathic pain. *Front Pharmacol*. 2022;12:769909.
34. Goyal S, Hamrah P. Understanding neuropathic corneal pain—gaps and current therapeutic approaches. *Semin Ophthalmol*. 2016;31:59–70.
35. Aggarwal S, Colon C, Kheirkhah A, Hamrah P. Efficacy of autologous serum tears for treatment of neuropathic corneal pain. *Ocul Surf*. 2019;17:532–539.
36. Saad S, Labani S, Goemaere I, et al. Corneal neurotization in the management of neurotrophic keratopathy: A review of the literature. *J Fr Ophthalmol*. 2023;46:83–96.
37. Wang Y, Kornberg DL, St Clair RM, et al. Corneal nerve structure and function after long-term wear of fluid-filled scleral lens. *Cornea*. 2015;34:427–432.
38. Finnerup NB, Otto M, McQuay H, et al. Algorithm for neuropathic pain treatment: an evidence based proposal. *Pain*. 2005;118:289–305.
39. Attal N, Cruccu G, Baron R, et al. EFNS guidelines on the pharmacological treatment of neuropathic pain: 2010 revision. *Eur J Neurol*. 2010;17:1113.e88.
40. Pappagallo M, Halley EJ. Pharmacological management of postherpetic neuralgia. *CNS Drugs*. 2003;17:771–780.
41. Derry S, Wiffen PJ, Aldington D, Moore RA. Nortriptyline for neuropathic pain in adults. *Cochrane Database Syst Rev*. 2015;1:CD011209.
42. De Freitas LF, Hamblin MR. Proposed mechanisms of photobiomodulation or low-level light therapy. *IEEE J Sel Top Quantum Electron*. 2016;22:348–364.
43. Chung H, Dai T, Sharma SK, et al. The nuts and bolts of low-level laser (light) therapy. *Ann Biomed Eng*. 2012;40:516–533.
44. Huang Y-Y, Chen AC-H, Carroll JD, Hamblin MR. Biphasic dose response in low level light therapy. *Dose Response*. 2009;7:358–383.
45. Wang C-Z, Chen Y-J, Wang Y-H, et al. Low-level laser irradiation improves functional recovery and nerve regeneration in sciatic nerve crush rat injury model. *PLOS One*. 2014;9:e103348.
46. Chow RT, Johnson MI, Lopes-Martins RA, Bjordal JM. Efficacy of low-level laser therapy in the management of neck pain: a systematic review and meta-analysis of randomised placebo or active-treatment controlled trials. *Lancet*. 2009;374:1897–1908.
47. Brosseau L, Welch V, Wells GA, et al. Low level laser therapy (classes I, II and III) for treating rheumatoid arthritis. *Cochrane Database Syst Rev*. 2005;4:CD002049.
48. Tumilty S, Munn J, McDonough S, et al. Low level laser treatment of tendinopathy: a systematic review with meta-analysis. *Photomed Laser Surg*. 2010;28:3–16.
49. Güngörmüş M, Akyol U. The effect of gallium-aluminum-arsenide 808-nm low-level laser therapy on healing of skin incisions made using a diode laser. *Photomed Laser Surg*. 2009;27:895–899.
50. Hamblin MR. Shining light on the head: photobiomodulation for brain disorders. *BBA Clin*. 2016;6:113–124.
51. Rosso MPdO, Buchaim DV, Kawano N, et al. Photobiomodulation therapy (PBMt) in peripheral nerve regeneration: a systematic review. *Bioengineering*. 2018;5:44.
52. Shen W, Teo KYC, Wood JPM, et al. Preclinical and clinical studies of photobiomodulation therapy for macular oedema. *Diabetologia*. 2020;63:1900–1915.
53. Kim H, Cho KJ. The effect of photobiomodulation with 830-nm LED on corneal alkali burnt rat model. *Lasers Med Sci*. 2024;39:81.
54. Uysal BS, Sankaya B, Dizakar SÖA, et al. Investigation of healing strategies in a rat corneal opacity model with polychromatic light and stem cells injection. *J Photochem Photobiol B*. 2024;253:112874.
55. Amaroli A, Ravera S, Baldini F, et al. Photobiomodulation with 808-nm diode laser light promotes wound healing of human endothelial cells through increased reactive oxygen species production stimulating mitochondrial oxidative phosphorylation. *Lasers Med Sci*. 2019;34:495–504.
56. Goo H, Kim H, Ahn JC, Cho KJ. Effects of low-level light therapy at 740 nm on dry eye disease in vivo. *Med Lasers*. 2019;8:50–58.
57. Deuis JR, Dvorakova LS, Vetter I. Methods used to evaluate pain behaviors in rodents. *Front Mol Neurosci*. 2017;10:284.
58. Ren K. An improved method for assessing mechanical allodynia in the rat. *Physiol Behav*. 1999;67:711–716.
59. Joubert F, Acosta MdC, Gallar J, et al. Effects of corneal injury on ciliary nerve fibre activity and corneal nociception in mice: a behavioural and electrophysiological study. *Eur J Pain*. 2019;23:589–602.
60. Farazifard R, Safarpour F, Sheibani V, Javan M. Eye-wiping test: a sensitive animal model for acute trigeminal pain studies. *Brain Res Protoc*. 2005;16:44–49.
61. Hamblin MR, Demidova TN. Mechanisms of low level light therapy. *Mech Low-Light Ther*. 2006;6140:614001.
62. Vladimirov YA, Gorbatenkova EA, Paramonov NV, Azizova OA. Photoreactivation of superoxide dismutase by intensive red (laser) light. *Free Rad Biol Med*. 1988;5:281–286.
63. Chaves MEDA, Araújo AR, Piancastelli ACC, Pinotti M. Effects of low-power light therapy on wound healing: LASER x LED. *An Bras Dermatol*. 2014;89:616–623.
64. Salehpour F, Mahmoudi J, Kamari F, et al. Brain photobiomodulation therapy: a narrative review. *Mol Neurobiol*. 2018;55:6601–6636.
65. Valter K, Tedford S, Eells JT, Tedford CE. Photobiomodulation use in ophthalmology—an overview of translational research from bench to bedside. *Front Ophthalmol*. 2024;4:1388602.
66. Bezinelli LM, Corrêa L, Vogel C, et al. Long-term safety of photobiomodulation therapy for oral mucositis in hematopoietic cell transplantation patients: a 15-year retrospective study. *Support Care Cancer*. 2021;29:6891–6902.
67. de Pauli Paglioni M, Araújo ALD, Arboleda LPA, et al. Tumor safety and side effects of photobiomodulation therapy used for prevention and management of cancer treatment toxicities. A systematic review. *Oral Oncol*. 2019;93:21–28.

68. Moro C, Torres N, Arvanitakis K, et al. No evidence for toxicity after long-term photobiomodulation in normal non-human primates. *Exp Brain Res*. 2017;235:3081–3092.
69. Hamblin MR. Mechanisms and applications of the anti-inflammatory effects of photobiomodulation. *AIMS Biophys*. 2017;4:337.
70. Gonçalves RB, Marques JC, Monte-Raso VV, et al. Effects of low-power laser on injured rat sciatic nerve regeneration. *Fisioter Pesqui*. 2010;17:34–39.
71. de Andrade ALM, Bossini PS, do Canto De Souza ALM, et al. Effect of photobiomodulation therapy (808 nm) in the control of neuropathic pain in mice. *Lasers Med Sci*. 2017;32:865–872.
72. Andreo L, Soldara C, Ribeiro B, et al. Effects of photobiomodulation on experimental models of peripheral nerve injury. *Lasers Med Sci*. 2017;32:2155–2165.
73. Navarro X, Vivó M, Valero-Cabré A. Neural plasticity after peripheral nerve injury and regeneration. *Prog Neurobiol*. 2007;82:163–201.
74. Devor M. Ectopic discharge in A β afferents as a source of neuropathic pain. *Exp Brain Res*. 2009;196:115–128.
75. Cruzat A, Pavan-Langston D, Hamrah P. In vivo confocal microscopy of corneal nerves: analysis and clinical correlation. *Semin Ophthalmol*. 2010;25:171–177.
76. Nishida T. Neurotrophic mediators and corneal wound healing. *Ocular Surf*. 2005;3:194–202.
77. Chucair-Elliott AJ, Zheng M, Carr DJ. Degeneration and regeneration of corneal nerves in response to HSV-1 infection. *Investig Ophthalmol Vis Sci*. 2015;56:1097–1107.
78. Enwemeka CS, Parker JC, Dowdy DS, et al. The efficacy of low-power lasers in tissue repair and pain control: a meta-analysis study. *Photomed Laser Ther*. 2004;22:323–329.
79. Campana VR, Moya M, Gavotto A, et al. The relative effects of He-Ne laser and meloxicam on experimentally induced inflammation. *Laser Ther*. 1999;11:36–42.
80. Karu T. Primary and secondary mechanisms of action of visible to near-IR radiation on cells. *J Photochem Photobiol B Biol*. 1999;49:1–17.